



# Καρκίνος τραχήλου

Χαράλαμπος Θεοφανάκης  
Γυναικολόγος – Ογκολόγος (ESGO)  
Επίκουρος Καθηγητής  
Γ' Μαιευτική & Γυναικολογική  
Κλινική ΕΚΠΑ  
ΠΓΝ Αττικών



# Καρκίνος τραχήλου μήτρας

Η τέταρτη πιο συχνή κακοήθεια στις γυναίκες

528.000 νέες περιπτώσεις ανά έτος

Μέση ηλικία διάγνωσης τα 48 έτη (35-55)

Νόσος που μπορεί να προληφθεί

Οι ασθενείς που διαγιγνώσκονται σε αρχόμενα στάδια έχουν αρκετές εναλλακτικές θεραπευτικές προσέγγισης

Η ριζική υστερεκτομή θεωρείται ορόσημο στην αντιμετώπιση αυτής της νόσου

Ferlay et al., *Int J Cancer*. 2015;136(5): E359-86

Ribeiro et al., *Int J Surg Oncol*. 2012;2012:36534

Ramirez et al., *Gynecol Oncol*. 2008;110(3 Suppl 2):S25-8



# Staging

DOI: 10.1002/ijgo.13865



FIGO CANCER REPORT 2021

## Cancer of the cervix uteri: 2021 update

Neerja Bhatla<sup>1</sup> | Daisuke Aoki<sup>2</sup> | Daya Nand Sharma<sup>3</sup> | Rengaswamy Sankaranarayanan<sup>4</sup>

### Box 1 FIGO staging of carcinoma of the cervix uteri (2018).

#### Stage I:

The carcinoma is strictly confined to the cervix uteri (extension to the corpus should be disregarded)

- **IA** Invasive carcinoma that can be diagnosed only by microscopy, with maximum depth of invasion <5 mm<sup>a</sup>
  - **IA1** Measured stromal invasion <3 mm in depth
  - **IA2** Measured stromal invasion ≥3 mm and <5 mm in depth
- **IB** Invasive carcinoma with measured deepest invasion ≥5 mm (greater than stage IA), lesion limited to the cervix uteri<sup>b</sup>
  - **IB1** Invasive carcinoma ≥5 mm depth of stromal invasion and <2 cm in greatest dimension
  - **IB2** Invasive carcinoma ≥2 cm and <4 cm in greatest dimension
  - **IB3** Invasive carcinoma ≥4 cm in greatest dimension

#### Stage II:

The carcinoma invades beyond the uterus, but has not extended onto the lower third of the vagina or to the pelvic wall

- **IIA** Involvement limited to the upper two-thirds of the vagina without parametrial involvement
  - **IIA1** Invasive carcinoma <4 cm in greatest dimension
  - **IIA2** Invasive carcinoma ≥4 cm in greatest dimension
- **IIB** With parametrial involvement but not up to the pelvic wall

#### Stage III:

The carcinoma involves the lower third of the vagina and/or extends to the pelvic wall and/or causes hydronephrosis or non-functioning kidney and/or involves pelvic and/or paraaortic lymph nodes<sup>c</sup>

- **IIIA** Carcinoma involves the lower third of the vagina, with no extension to the pelvic wall
- **IIIB** Extension to the pelvic wall and/or hydronephrosis or non-functioning kidney (unless known to be due to another cause)
- **IIIC** Involvement of pelvic and/or paraaortic lymph nodes, irrespective of tumor size and extent (with r and p notations)<sup>c</sup>
  - **IIIC1** Pelvic lymph node metastasis only
  - **IIIC2** Paraaortic lymph node metastasis

#### Stage IV:

The carcinoma has extended beyond the true pelvis or has involved (biopsy proven) the mucosa of the bladder or rectum. A bullous edema, as such, does not permit a case to be allotted to stage IV

- **IVA** Spread of the growth to adjacent organs
- **IVB** Spread to distant organs

<sup>a</sup>Imaging and pathology can be used, when available, to supplement clinical findings with respect to tumor size and extent, in all stages.

<sup>b</sup>The involvement of vascular/lymphatic spaces does not change the staging. The lateral extent of the lesion is no longer considered.

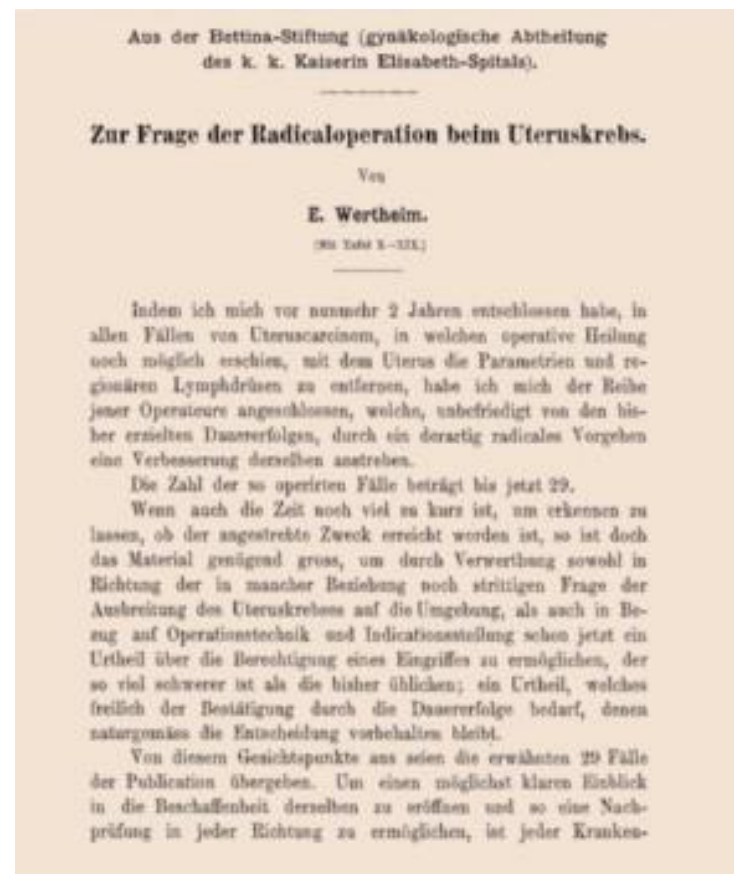<sup>c</sup>Adding notation of r (imaging) and p (pathology) to indicate the findings that are used to allocate the case to stage IIIC. For example, if imaging indicates pelvic lymph node metastasis, the stage allocation would be stage IIIC1r and, if confirmed by pathological findings, it would be Stage IIIC1p. The type of imaging modality or pathology technique used should always be documented. When in doubt, the lower staging should be assigned.

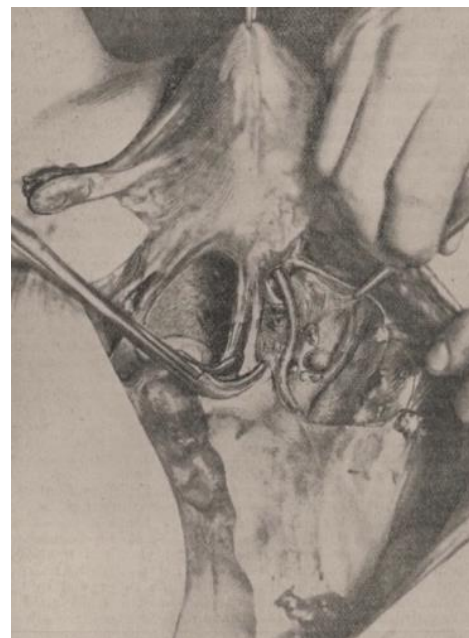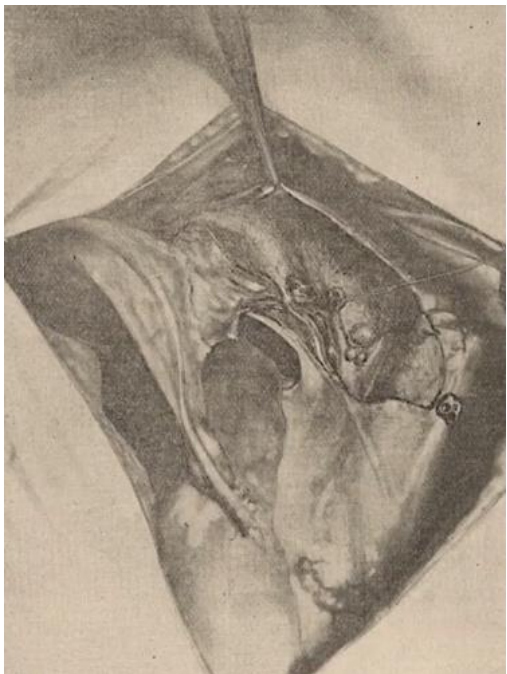
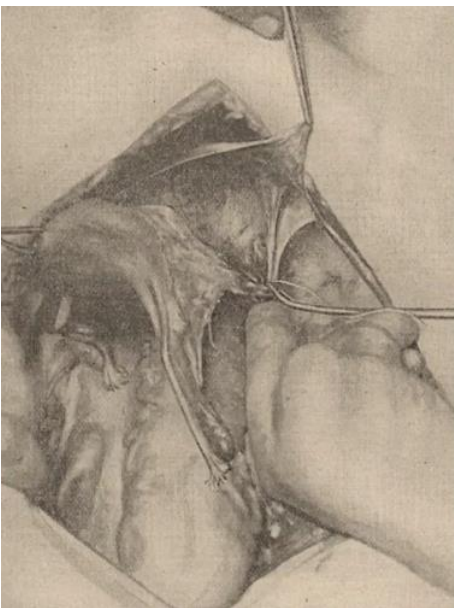
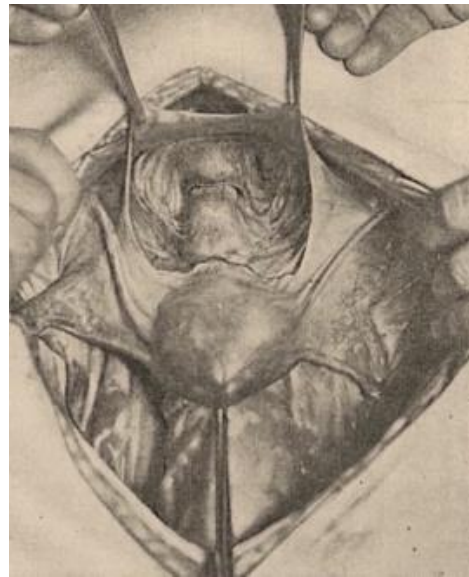
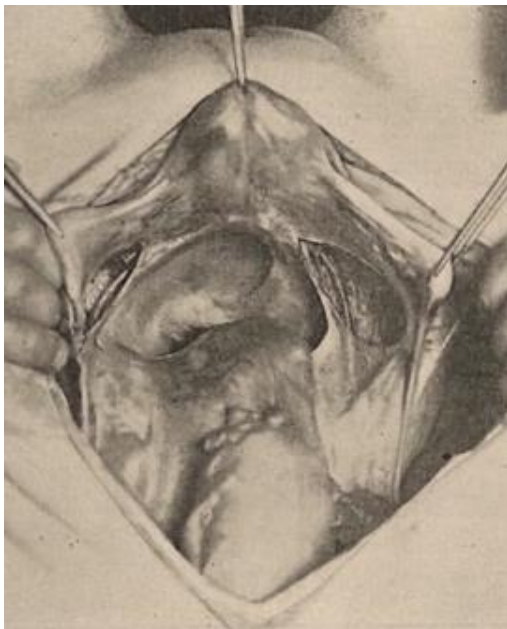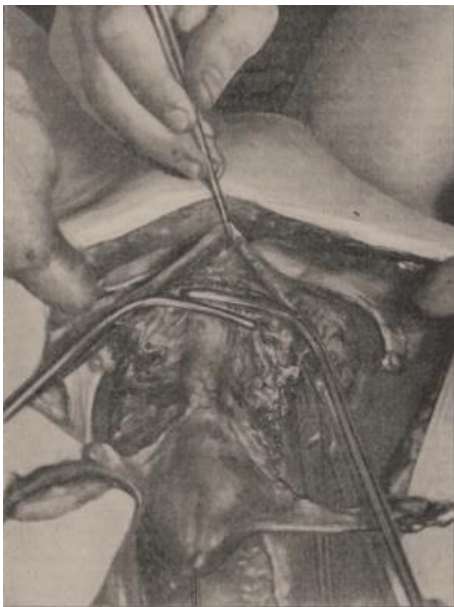




# Η αρχή: Ernst Wertheim, 1864-1920


- 16 Νοεμβρίου 1898: Ο Wertheim, σε ηλικία 34 ετών πραγματοποιεί την πρώτη κοιλιακή ριζική υστερεκτομή σε ασθενή με καρκίνο τραχήλου μήτρας
- Η επέμβαση διήρκησε 3 ώρες και η 39 ετών ασθενής και μητέρα 5 παιδιών κατέληξε 8 ώρες μετά, λόγω εκσεσημασμένης απώλειας αίματος







# Οι πρώτες 500 επεμβάσεις



Wertheim results	1898-1910
Total N ambulatory cervical cancers	>1000
Surgical candidates - operability	49 %
% of operative mortality	18.6 %
First- 100 cases op mortality	30 %
% of relapses (follow-up 5 y)	31 %
Survival at 5 y	42.9 %
Total accomplishments at 5 years <b>Winter formula</b> (operability, surgical mortality and % of alive without disease)	18.5 %

Wertheim complications	N out 500
Retroperitoneal abscess	18
Ureterovaginal fistula	32
Bilateral ureteral fistula	5
Vesicovaginal fistula	16
Peritonitis	33
Severe Pyelonephritis	9
Embolism	5
Postoperative deaths	93 (18.6 %)



# Η Ιαπωνική Σχολή. 1920

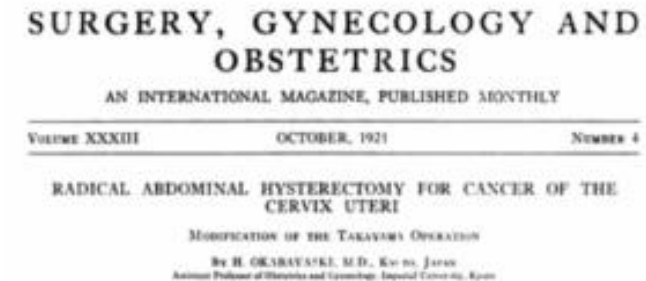


Fig. 6. Specimen of squamous-celled carcinoma of the cervix in the advanced stage. This tumor was removed by the author and the result has been very satisfactory. The disease had spread in all directions and the parametrium was very much thickened due to the carcinomatous infiltration. Some enlarged lymph glands are visible within. The upper half of the posterior wall of the vagina is invaded by the growth.





# Η Ιαπωνική Σχολή. 1920

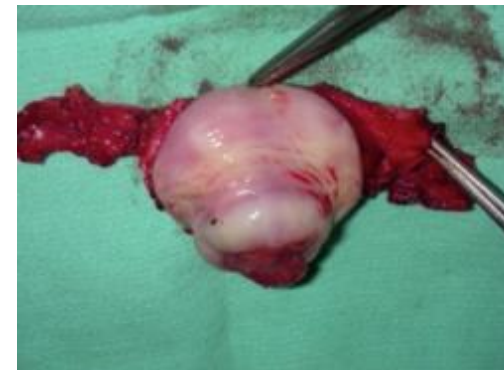- Ο Okabayashi πραγματοποίησε 3000 επεμβάσεις σε διάστημα 15 ετών
- Μέση διάρκεια επέμβασης: 2 ώρες
- Εκτεταμένη εκτομή παραμητρίου
- Παρασκευή του οπισθίου πετάλου του κυστεομητρικού συνδέσμου





# Prof. D. Dargent (1937 – 2005)

- Πρωτοπόρος στη λαπαροσκόπηση στη Γυναικολογική Ογκολογία
- Σχεδιάσε τη λαπαροσκοπικά υποβοηθούμενη κοιλιακή ριζική τραχηλεκτομή
- Ένας από τους πρώτους που εισήγαγε την τεχνική του φρουρού λεμφαδένα στον καρκίνο του τραχήλου





## Classification of radical hysterectomy

*Denis Querlev, C Paul Morrow*

Since the first publications about surgery for cervical cancer, many radical procedures that accord with different degrees of radicality have been described and done. Here, we propose a basis for a new and simple classification for cervical-cancer surgery, taking into account the curative effect of surgery and adverse effects, such as bladder dysfunction. The international anatomical nomenclature is used where it applies. For simplification, the classification is based only on lateral extent of resection. We describe four types of radical hysterectomy (A–D), adding when necessary a few subtypes that consider nerve preservation and paracervical lymphadenectomy. Lymph-node dissection is considered separately: four levels (1–4) are defined according to corresponding arterial anatomy and radicality of the procedure. The classification applies to fertility-sparing surgery, and can be adapted to open, vaginal, laparoscopic, or robotic surgery. In the future, internationally standardised description of techniques for communication, comparison, clinical research, and quality control will be a basic part of every surgical procedure.

**Lancet Oncol 2008; 9: 297–303**



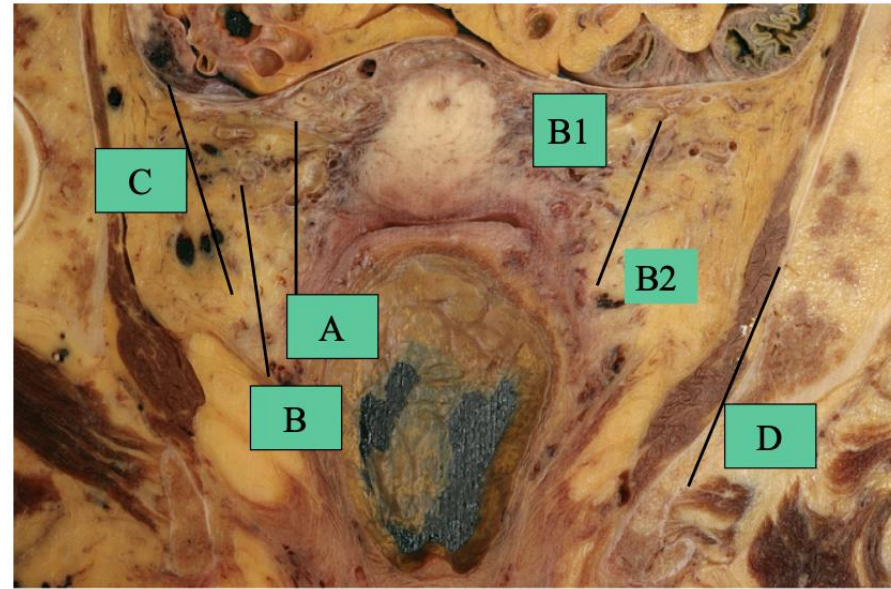
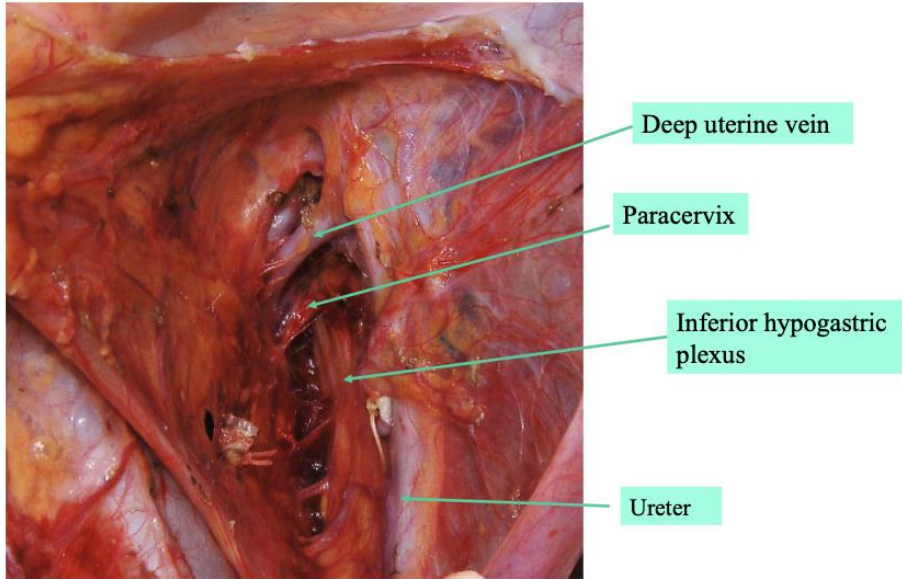
ORIGINAL ARTICLE – GYNECOLOGIC ONCOLOGY

## 2017 Update on the Querleu–Morrow Classification of Radical Hysterectomy

Denis Querleu, MD<sup>1</sup>, David Cibula, MD<sup>2</sup>, and Nadeem R. Abu-Rustum, MD<sup>3,4</sup>

<sup>1</sup>Department of Surgery, Institut Bergonié, Bordeaux, France; <sup>2</sup>Charles University, Prague, Czech Republic; <sup>3</sup>Department of Surgery, Memorial Sloan Kettering Cancer Center, New York, NY; <sup>4</sup>Weill Cornell Medical School, New York, NY

Dimension Type of radical hysterectomy	Paracervix or lateral parametrium	Ventral parametrium	Dorsal parametrium
A	Halfway between the cervix and ureter (medial to the ureter–ureter identified but not mobilized)	Minimal excision	Minimal excision
B1	At the ureter (at the level of the ureteral bed–ureter mobilized from the cervix and lateral parametrium)	Partial excision of the vesicouterine ligament	Partial resection of the rectouterine-rectovaginal ligament and uterosacral peritoneal fold
B2	Identical to B1 plus paracervical lymphadenectomy without resection of vascular/nerve structures	Partial excision of the vesicouterine ligament	Partial resection of the rectouterine-rectovaginal ligament and uterosacral fold
C1	At the iliac vessels transversally, caudal part is preserved	Excision of the vesicouterine ligament at the bladder. Proximal part of the vesicovaginal ligament (bladder nerves are dissected and spared)	At the rectum (hypogastric nerve is dissected and spared)
C2	At the level of the medial aspect of iliac vessels completely (including the caudal part)	At the bladder (bladder nerves are sacrificed)	At the sacrum (hypogastric nerve is sacrificed)
D	At the pelvic wall, including resection of the internal iliac vessels and/or components of the pelvic sidewall	At the bladder. Not applicable if part of exenteration	At the sacrum. Not applicable if part of exenteration



# SENTIX Study

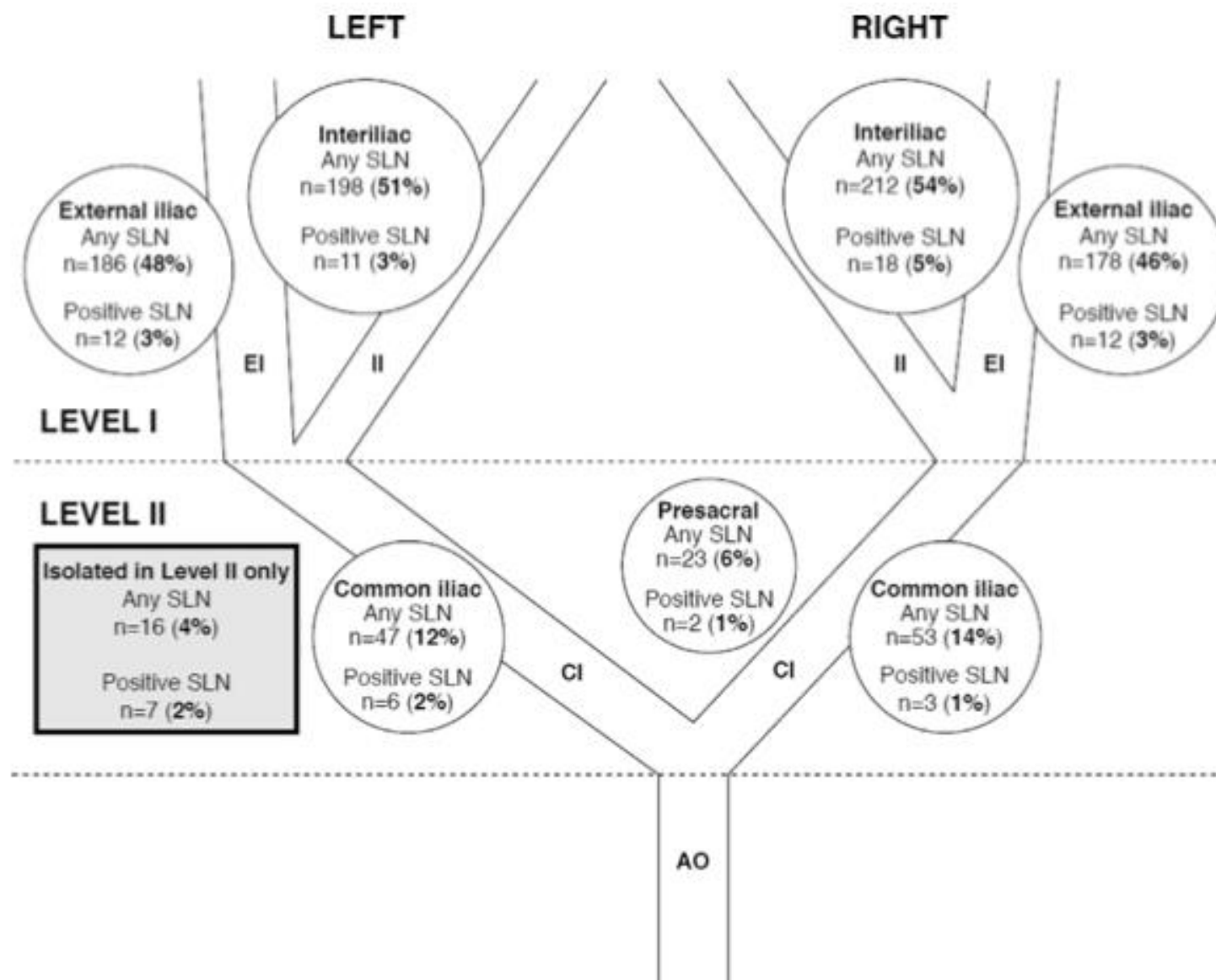


Original Research

Sentinel lymph node mapping and intraoperative assessment in a prospective, international, multicentre, observational trial of patients with cervical cancer: The SENTIX trial



David Cibula <sup>a,\*</sup>, Roman Kocian <sup>a,1</sup>, Andrea Plaikner <sup>b</sup>, Jiri Jarkovsky <sup>c</sup>, Jaroslav Klat <sup>d,1</sup>, Ignacio Zapardiel <sup>e</sup>, Radovan Pilka <sup>f,1</sup>, Aureli Torne <sup>g</sup>, Borek Sehnal <sup>h,1</sup>, Marcela Ostojich <sup>i</sup>, Almerinda Petiz <sup>j</sup>, Octavio A. Sanchez <sup>k</sup>, Jiri Presl <sup>l,1</sup>, Alessandro Buda <sup>m</sup>, Francesco Raspagliesi <sup>n</sup>, Peter Kascak <sup>o,1</sup>, Luc van Lonkhuijzen <sup>p</sup>, Marc Barahona <sup>q</sup>, Lubos Minar <sup>r,1</sup>, Pawel Blecharz <sup>s,1</sup>, Maja Pakiz <sup>t,1</sup>, Dariusz Wydra <sup>u,1</sup>, Leon C. Snyman <sup>v</sup>, Kamil Zalewski <sup>w,1</sup>, Cristina Zorrero <sup>x</sup>, Pavel Havelka <sup>y,1</sup>, Mikulas Redecha <sup>z,1</sup>, Alla Vinnytska <sup>aa,1</sup>, Ignace Vergote <sup>ab,2</sup>, Solveig Tingulstad <sup>ac</sup>, Martin Michal <sup>ad,1</sup>, Barbara Kipp <sup>ae</sup>, Jiri Slama <sup>a,1</sup>, Simone Marnitz <sup>af</sup>, Sylva Bajsova <sup>d</sup>, Alicia Hernandez <sup>e</sup>, Daniela Fischerova <sup>a,1</sup>, Kristyna Nemejcova <sup>ag</sup>, Christhardt Kohler <sup>b</sup>





# SENTIX Study

Type of SLN involvement	SLN status (no. of patients)			SLN frozen section outcome (%)		
	Frozen section	Ultrastaging	Final status*	Sensitivity	False negatives	NPV
Macrometastases →	21	8	29	72.4	27.6	97.8
Micrometastases	2	19	21	9.5	90.5	94.7
Isolated tumour cells	0	12	12	0	100	96.7
Macrometastases + Micrometastases →	23	27	50	46.0	54.0	92.5
Macrometastases + Micrometastases + Isolated tumour cells	23	39	62	37.1	62.9	89.2

SLN detection (N = 391).

Variables	Value
SLN detection per pelvic side	
None or unilateral	36 (9.2%)
Bilateral	355 (90.8%)
Detection method	
Not applicable	2 (0.5%)
Blue dye	58 (14.8%)
Radiocolloid	14 (3.6%)
Indocyanine green	59 (15.1%)
Blue dye + radiocolloid	141 (36.1%)
Blue dye + indocyanine green	51 (13.0%)
Radiocolloid + indocyanine green	36 (9.2%)
Blue dye + radiocolloid + indocyanine green	30 (7.7%)
No. of SLN per patient	
0	10 (2.7%)
1	6 (1.6%)
2	121 (32.1%)
3	85 (22.5%)
4	52 (13.8%)
>4	103 (27.6%)
Median no. of SLN per patient	3 (2–12)
No. of patients with positive SLN	
Total	62 (16.5%)
Bilateral SLN	59 (15.6%)
Unilateral SLN	3 (0.8%)
No. of positive SLN	
0	316 (83.8%)
1	47 (12.5%)
2	11 (2.9%)
3	4 (1.1%)

Values are no. of patients (%) or median (5th–95th percentile).  
SLN, sentinel lymph node.


## N = 600

- Η ταχεία βιοψία του SLN δεν διέγνωσε το 27.6% των μακρομεταστάσεων, το 90.5% των μικρομεταστάσεων και συνολικά το 54% των θετικών λεμφαδένων
- **6.7%** στην τελική ιστολογική



## Sentinel lymph node biopsy in early stage cervical cancer: A meta-analysis

Xinyue Zhang | Bingting Bao | Sixue Wang | Mingyu Yi | Li Jiang | Xiaoling Fang 



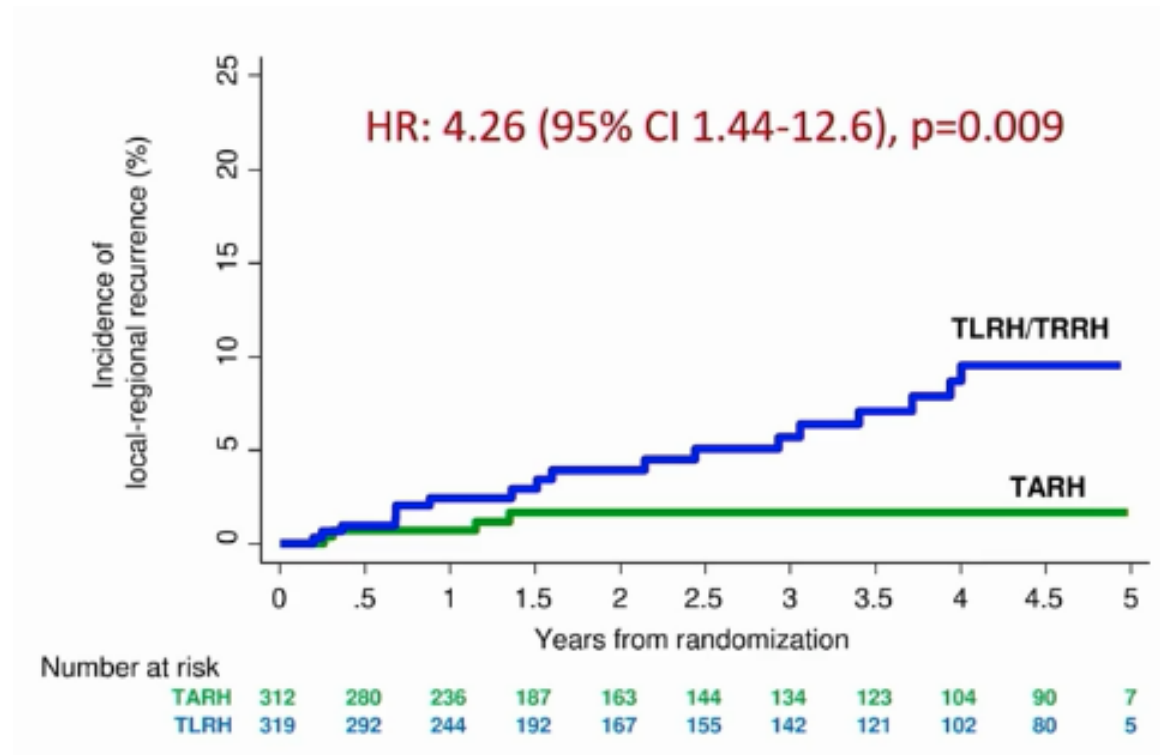
- Ο φρουρός λεμφαδένας αποτελεί μέθοδο με υψηλή διαγνωστική ικανότητα αν χρησιμοποιηθεί το σωστό μέσο σκιαγράφησης και σε επιλεγμένη ομάδα ασθενών
- Η ICG φαίνεται ότι υπερτερεί έναντι των άλλων τεχνικών



ORIGINAL ARTICLE

## Minimally Invasive versus Abdominal Radical Hysterectomy for Cervical Cancer

Pedro T. Ramirez, M.D., Michael Frumovitz, M.D., Rene Pareja, M.D., Aldo Lopez, M.D., Marcelo Vieira, M.D., Reitan Ribeiro, M.D., Alessandro Buda, M.D., Xiaojian Yan, M.D., Yao Shuzhong, M.D., Naven Chetty, M.D., David Isla, M.D., Mariano Tamura, M.D., Tao Zhu, M.D., Kristy P. Robledo, Ph.D., Val GebSKI, M.Stat., Rebecca Asher, M.Sc., Vanessa Behan, B.S.N., James L. Nicklin, M.D., Robert L. Coleman, M.D., and Andreas Obermair, M.D.

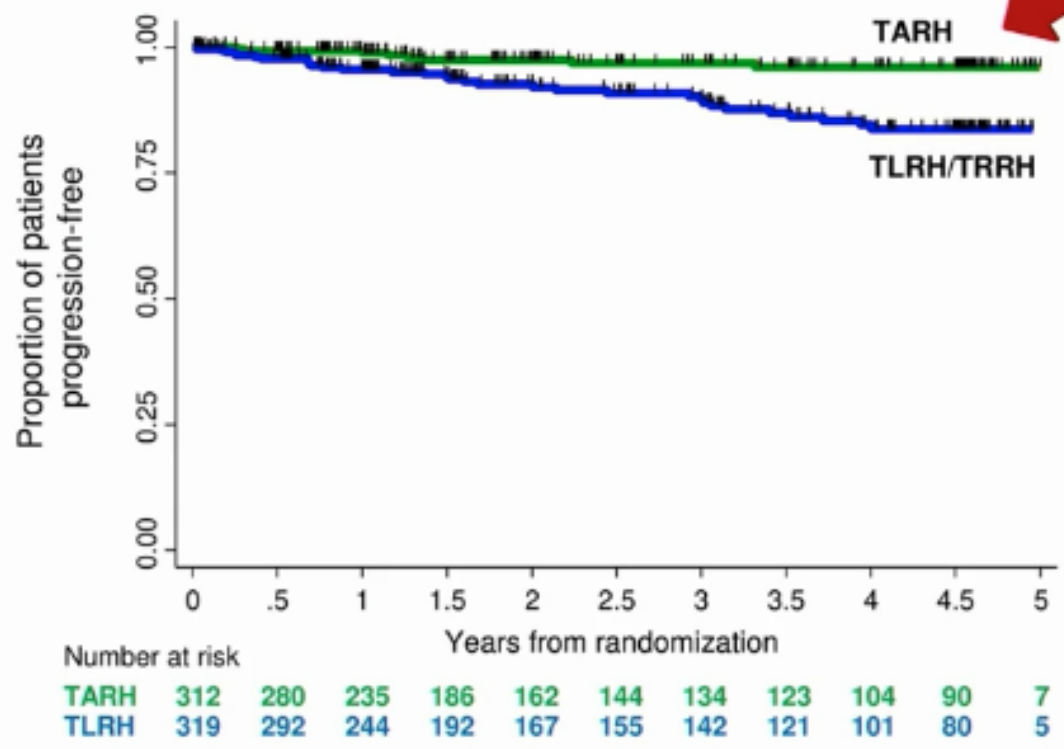


Level A

Quality of surgery matters!!!



# LACC trial: PFS



**Progression-Free Survival (PFS)**  
HR: 3.88 (95% CI: 1.79 - 8.41), p<0.001

Events/N  
TARH: 8/312  
TLRH/TRRH: 32/319









Original research



OPEN ACCESS

# ESGO/ESTRO/ESP Guidelines for the management of patients with cervical cancer – Update 2023\*

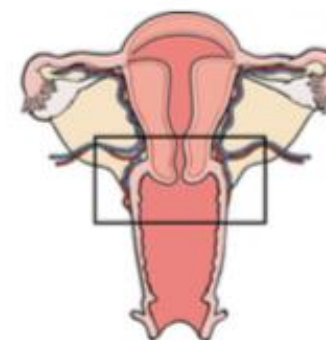
David Cibula,<sup>1,2</sup> Maria Rosaria Raspollini,<sup>3</sup> François Planchamp ,<sup>4</sup> Carlos Centeno,<sup>5</sup> Cyrus Chargari ,<sup>6</sup> Ana Felix,<sup>7,8</sup> Daniela Fischerová ,<sup>1,2</sup> Daniela Jahnn-Kuch,<sup>9</sup> Florence Joly,<sup>10</sup> Christhardt Kohler,<sup>11,12</sup> Sigurd Lax,<sup>13,14</sup> Domenica Lorusso,<sup>15,16</sup> Umesh Mahantshetty,<sup>17</sup> Patrice Mathevet,<sup>18</sup> Raj Naik,<sup>19</sup> Remi A Nout,<sup>20,21</sup> Ana Oaknin ,<sup>22,23</sup> Fedro Peccatori,<sup>24</sup> Jan Persson,<sup>25,26</sup> Denis Querleu ,<sup>15,27</sup> Sandra Rubio Bernabé ,<sup>28</sup> Maximilian P Schmid,<sup>29</sup> Artem Stepanyan ,<sup>30</sup> Valentyn Svintsitskyi,<sup>31</sup> Karl Tamussino,<sup>32</sup> Ignacio Zapardiel ,<sup>33</sup> Jacob Lindegaard<sup>34</sup>



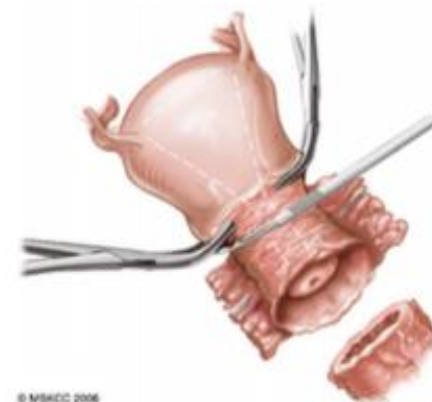


# Radical Trachelectomy-Indications

1. Desire for fertility-preservation
2. Confirmation by pathology
3. Squamous, adenosquamous, HPV-related adenocarcinoma
4. Tumor size < 2 cm
5. St IA1, LVSI(+) / St IA2 / St IB1
6. Tumor confined to the cervix (MRI)
7. Negative LNDs by CT or PET-CT
8. No history of infertility



© MSHCC 2006



© MSHCC 2006

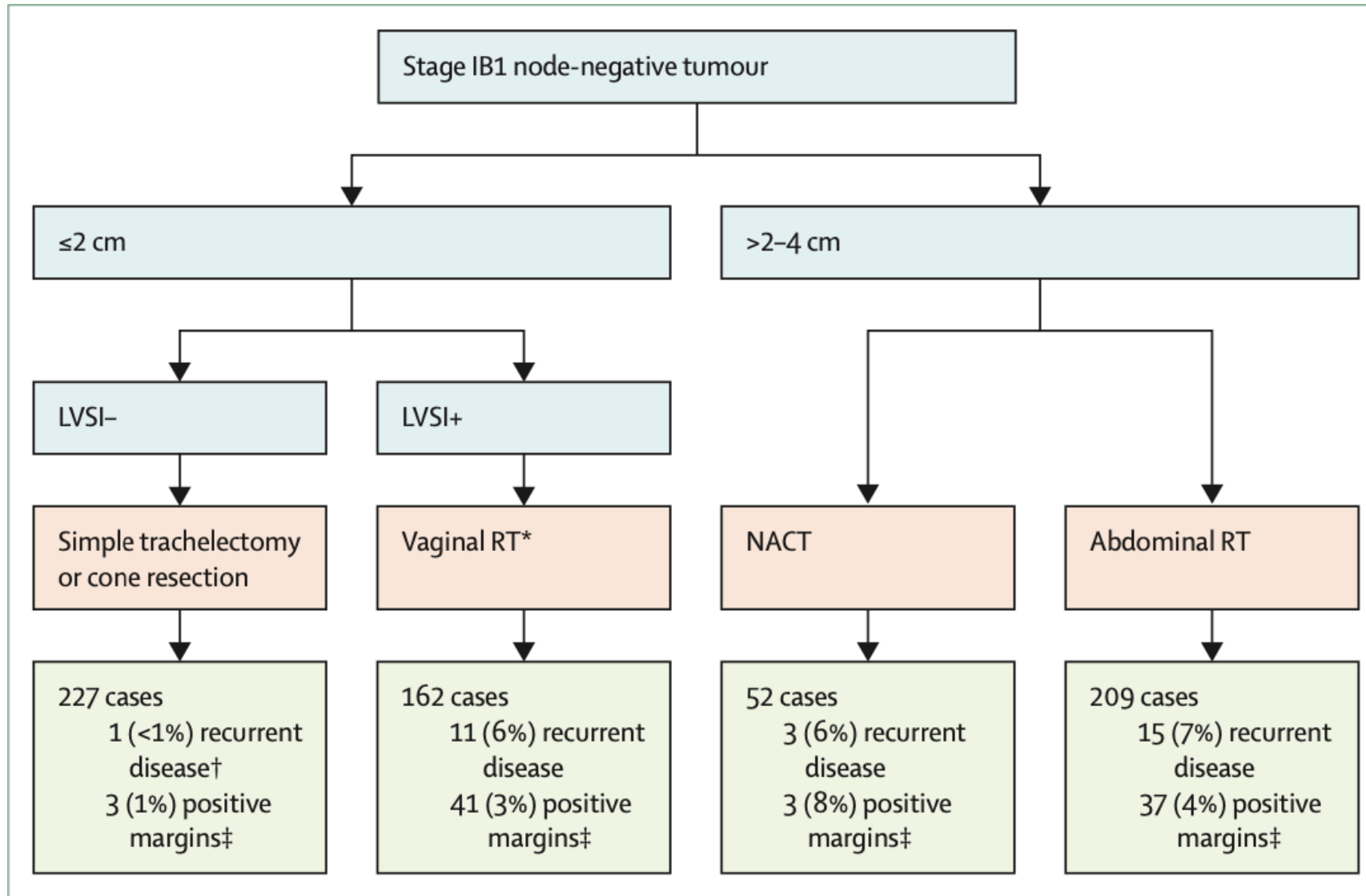
Abu-Rustum et al., Gynecol Oncol 2006



# Oncological outcomes after fertility-sparing surgery for cervical cancer: a systematic review



Enrica Bentivegna, Sebastien Gouy, Amandine Maulard, Cyrus Chargari, Alexandra Leary, Philippe Morice

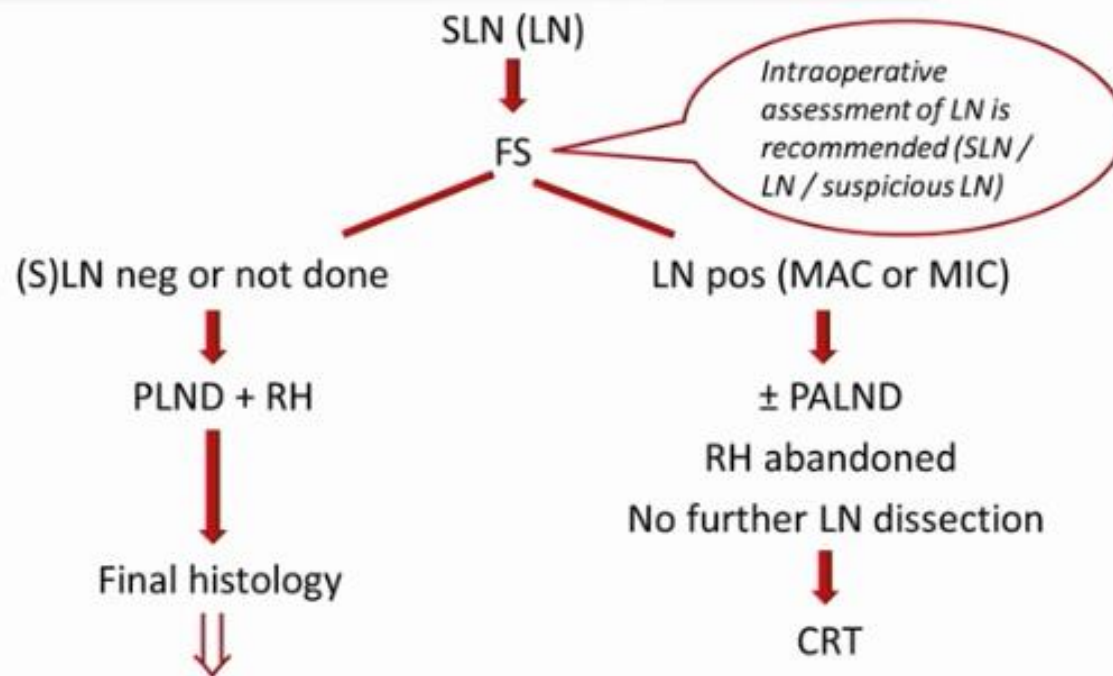




# Διεγχειρητική εκτίμηση των λεμφαδένων



St IB1 – IIA1





- ▶ Fertility sparing therapy is an oncologically valid alternative to radical hysterectomy for young patients with cervical cancer <2 cm (squamous cell carcinoma and HPV-related adenocarcinoma) who want to preserve the option to have children. Before initiating fertility sparing therapy, consultation at an onco-fertility center and discussion in a multidisciplinary tumor board is recommended [III, B].
- ▶ Counseling of eligible patients should encompass the oncologic and obstetric risks related to this type of management as well as the risk of fertility sparing therapy abandonment if there are positive resection margins or LN involvement [III, A].





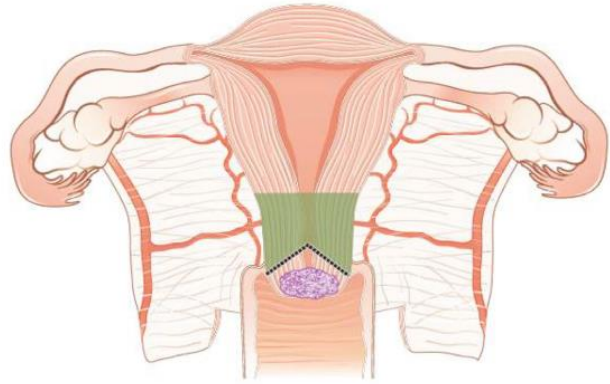
- ▶ Fertility-sparing treatment should be performed exclusively in gynaecological-oncological centers with comprehensive expertise in all types of these surgical procedures [IV, A].
- ▶ Fertility-sparing treatment should not be recommended for uncommon and rare histological types/subtypes of cervical cancer with aggressive behavior including neuroendocrine carcinomas, HPV-independent adenocarcinomas and carcinosarcomas [V, D].
- ▶ For patients who consider fertility sparing therapy, prognostic factors, clinical staging, and preoperative work-up do not differ from those not considering fertility sparing therapy (see above). Pelvic MRI and/or expert sonography are mandatory imaging tests to measure the non-involved cervical length (upper tumor free margin) and the remaining (after cone biopsy) cervical length [III, A].
- ▶ Negative PLN status is the precondition for any fertility sparing therapy. Therefore, PLN staging (SLN) should always be the first step in each fertility-sparing therapy procedure. Identification of SLN and its ultrastaging is highly recommended. Any intraoperative suspicious LN (apart from SLN) should also be removed. If SLN cannot be detected on either pelvic side, a systematic pelvic lymphadenectomy should be performed on that side. Intraoperative assessment of LN status is highly recommended. All SLN from both sides of the pelvis and any suspicious LN should be sent for frozen section. LN staging is not indicated in T1a1 LVSI negative [III, A].
- ▶ In case of intraoperatively proven PLN involvement, fertility-sparing surgery should be abandoned and patients should be referred for CTRT and BT [IV, B]. PALND, at least up to inferior mesenteric artery, may be considered for staging purposes [IV, C]. Ovarian transposition cannot be recommended in N1 status [IV, D].



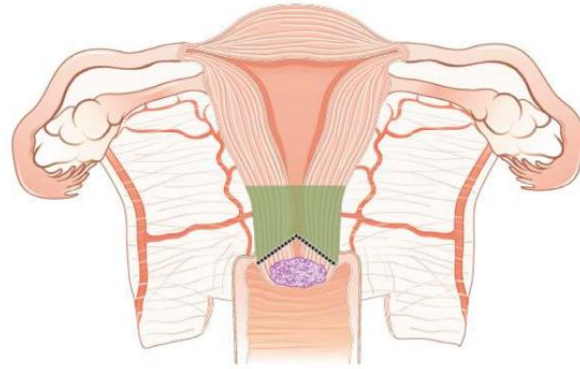


- ▶ The specific goal of fertility-sparing surgery must be resection of invasive tumor with adequate free margins and preservation of the upper part of the cervix [IV, A]. Intraoperative frozen section is a feasible way of assessing the upper resection margin [IV, C].
- ▶ LN staging follows the principles of management of early stages [III, B].
- ▶ Conization and simple trachelectomy are adequate fertility sparing procedures in patients with T1a1 and T1a2 tumors, regardless of LVSI status [IV, B].
- ▶ Conization or simple trachelectomy are adequate fertility sparing procedures for T1b1, LVSI negative tumors. Radical trachelectomy is still an option [IV, B].
- ▶ Radical trachelectomy (type B) should be performed in patients with cervical cancer T1b1, LVSI-positive. In patients without deep stromal involvement and with a high probability of adequate endocervical tumor free margins, simple trachelectomy can be considered [III, B].
- ▶ Intraoperative placement of permanent cerclage should be performed during simple or radical trachelectomy [IV, B].

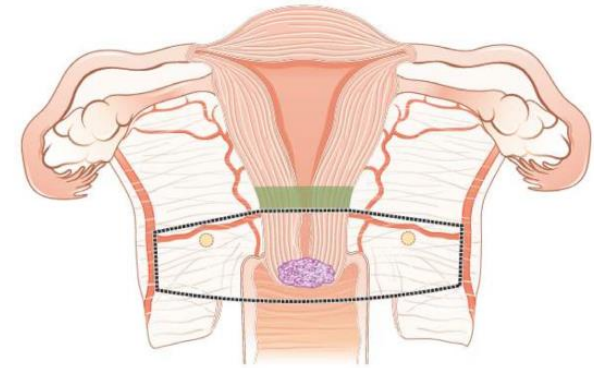




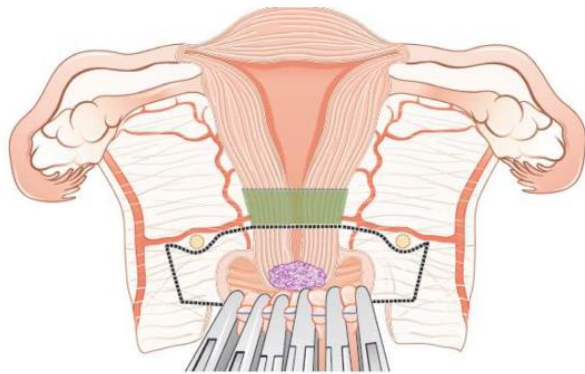
Conization



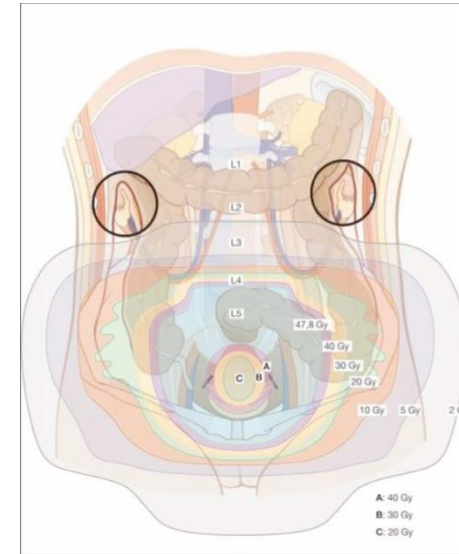
Simple trachelectomy



Radical abdominal trachelectomy



Radical vaginal trachelectomy



Ovarian transposition



- ▶ Fertility sparing therapy for patients with tumors greater than 2 cm is significantly associated with a higher risk of recurrence and should not be considered as a standard treatment. The risk of recurrence must be comprehensively discussed with the patient. NACT followed by radical vaginal trachelectomy and abdominal radical trachelectomy or cone has been described for fertility sparing treatment in patients with tumors >2 cm. PLN staging should be performed before starting NACT to confirm tumor-free LN. The optimal number of chemotherapy cycles, chemotherapy regimen as well as extent of cervical resection following NACT, are still a matter of debate [IV, B].
- ▶ In more advanced cases, various fertility preservation proposals such as ovarian transposition (see [Figure 7](#)), oocyte-, embryo- or ovarian tissue preservation and egg donation should be discussed with the patient. The aim of the fertility preservation should be to offer the most efficient approach in accordance with the legal country-specific regulations, while not increasing the oncological risk [IV, B].
- ▶ Any pregnancy following fertility sparing therapy should be considered as a high-risk pregnancy. Following simple or radical trachelectomy with placement of a permanent cerclage, delivery can only be performed by cesarean section [IV, B].





- ▶ Routine hysterectomy after completion of childbearing is not mandatory [V, D].





# Preoperative work-up

## Locally confined disease

- Clinical examination under anesthesia and biopsies
- Pelvic MRI or TV-U/S


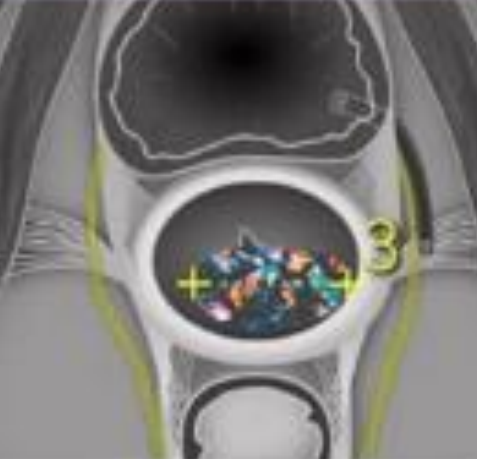
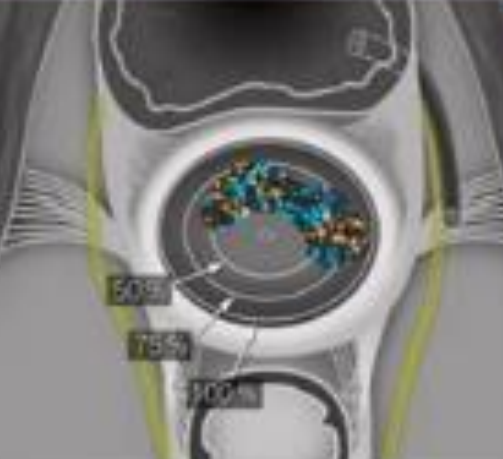
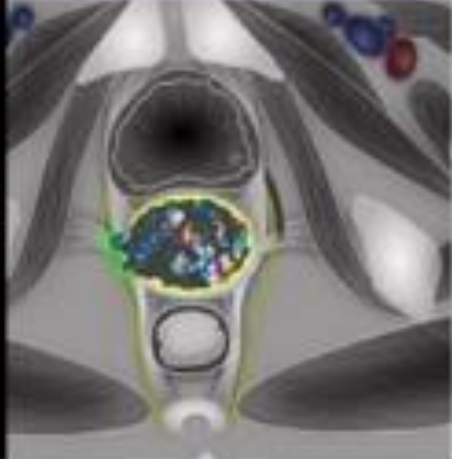


## Lymph node assessment and distant metastases

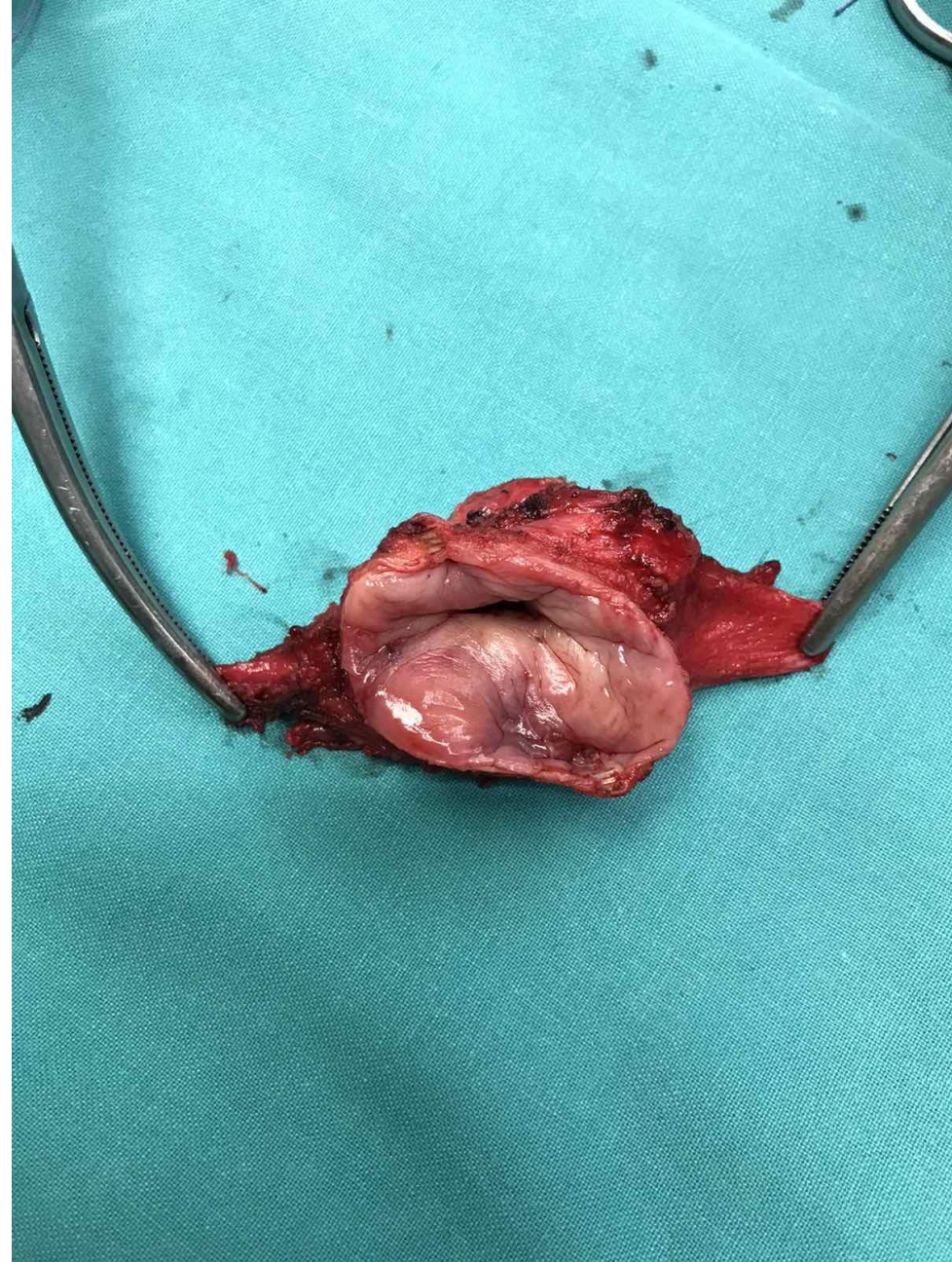
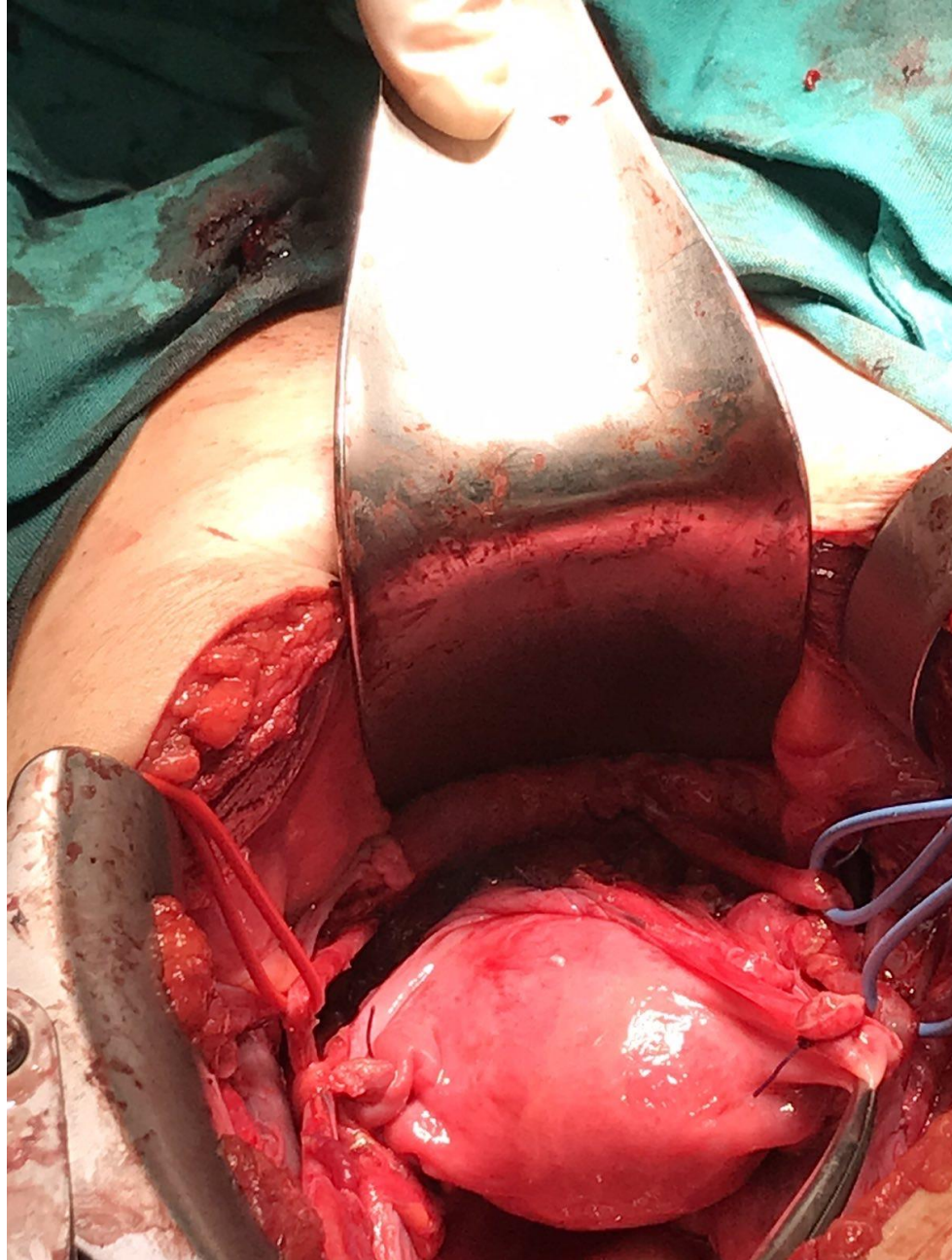
- PET-CT or CT chest/abdomen





Tumor detection	Tumor size measurements	Stromal invasion depth	Parametrial invasion
			
<p>Agreement with histology</p> <p>Ultrasound vs MRI</p> <p>96 vs 86%</p> <p><math>P \leq 0.001</math></p>	<p>Agreement with histology</p> <p>Ultrasound vs MRI</p> <p>95 vs 93%</p> <p><math>P = 0.10</math></p>	<p>Agreement with histology</p> <p>Ultrasound vs MRI</p> <p>91 vs 88%</p> <p><math>P = 0.39</math></p>	<p>Agreement with histology</p> <p>Ultrasound vs MRI</p> <p>97 vs 90%</p> <p><math>P \leq 0.001</math></p>







# St IA2 – IB1

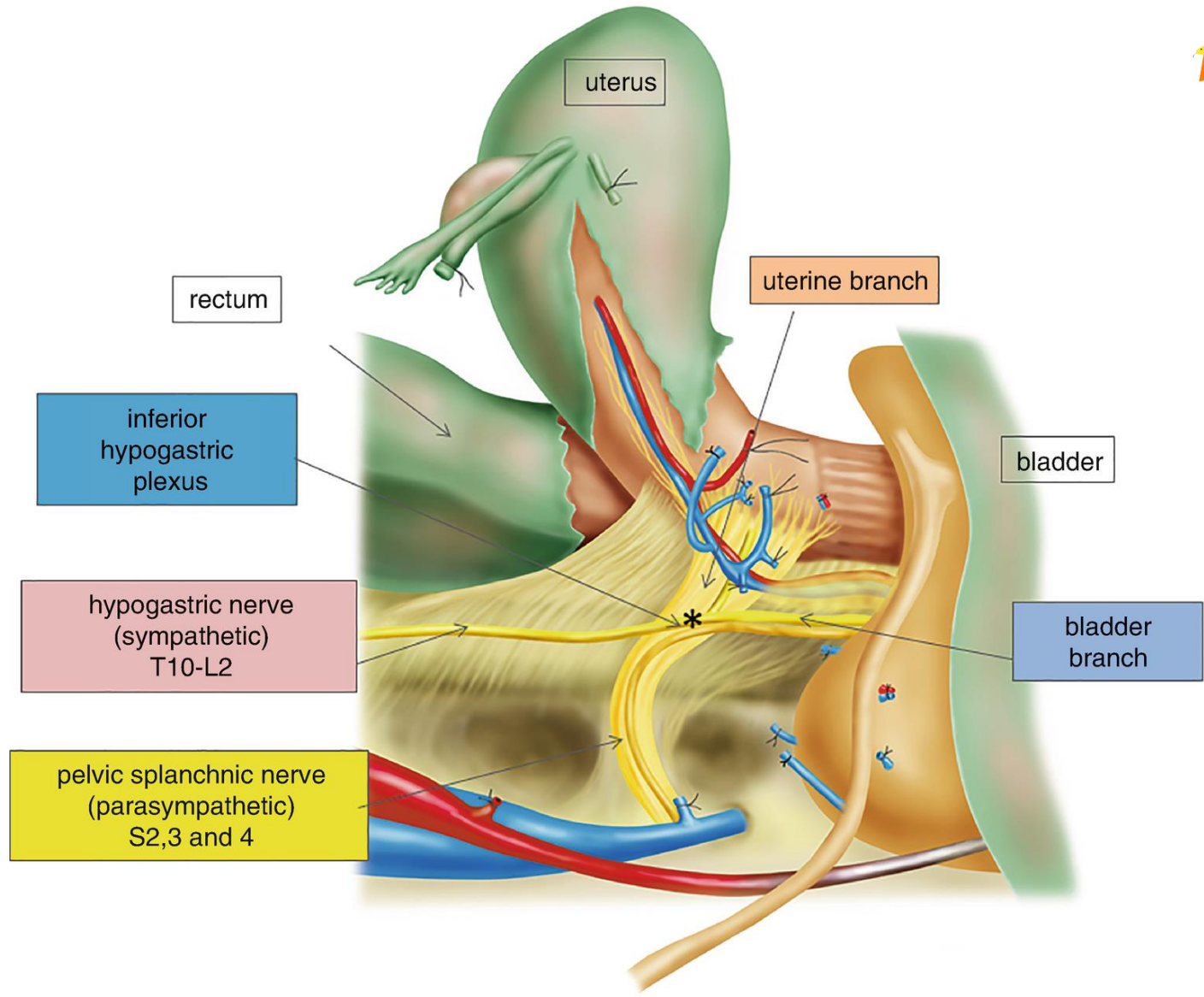
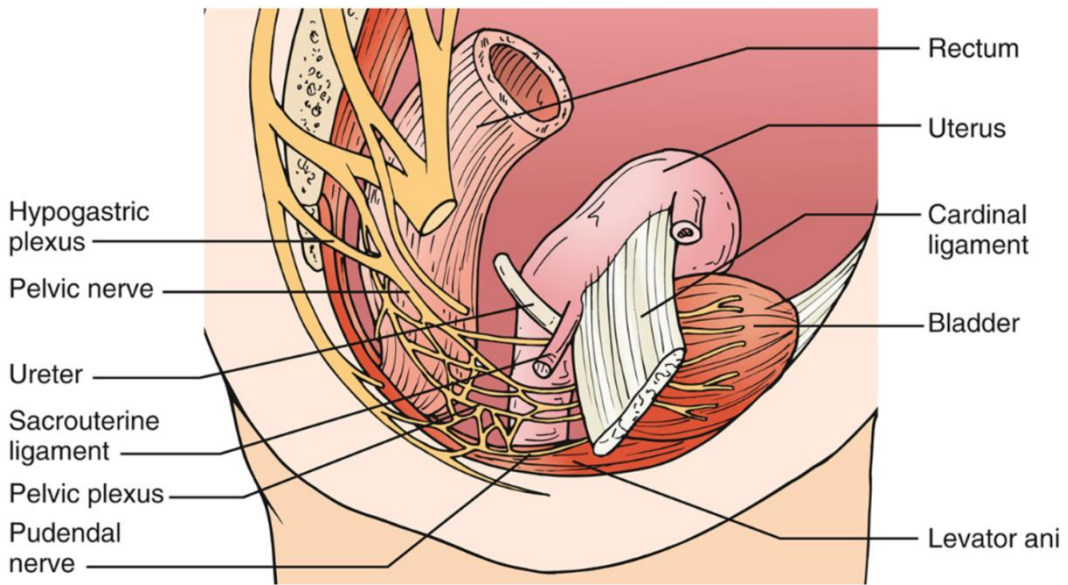
Radical trachelectomy

Or not???

*Alternatives*

Conization / simple trachelectomy







# Radical surgery

- Constipation 9-18%
- Urinary Incontinence 33%
- Dyspareunia (18 - 42%)
- Vaginal dryness (10 - 55%)
- ↓ Need for sex (31%)
- ↓ Vaginal shortness (25 - 29%)
- ↑ stress due to CaCx and sexual dysfunction
  - ↓ Interest (25 – 66%), ↓ pleasure, ↑ anxiety for future intercourses (53%)
- ↓ Sexual activity (91%)
- ↓ Frequency of intercourses
- ↓ QoL





# Parametrial Involvement

Gynecologic Oncology **84**, 145–149 (2002)

doi:10.1006/gyno.2001.6493, available online at <http://www.idealibrary.com> on **IDEAL**<sup>®</sup>



## How Important Is Removal of the Parametrium at Surgery for Carcinoma of the Cervix?<sup>1</sup>

A. Covens, M.D.,<sup>2</sup> B. Rosen, M.D., J. Murphy, M.D., S. Laframboise, M.D., A. D. DePetrillo, M.D., G. Lickrish, M.D., T. Colgan, M.D.,\* W. Chapman, M.D.,\* and P. Shaw M.D.\*

*Department of Obstetrics and Gynecology, Division of Gynecologic Oncology, and \*Department of Pathology, University of Toronto, Toronto–Sunnybrook Regional Cancer Centre, University Health Network, and Sunnybrook and Women's College Health Science Centre, Toronto, Ontario M4N 3M5, Canada*

Received February 20, 2001





# Parametrial Involvement

- 842 pts – radical hysterectomy
- St IA1 – IB1
- 33 pts (4%) → parametrial involvement



- *Large tumors*
- *LVSI (+)*
- *Depth of Invasion*
- *PLNDs (+)*

Covens et al., *Gynecol Oncol* 2002;84:145-149





## Parametrial Involvement

- **Sub-group analysis of 536 pts with:**
  - Tumor size  $\leq 2$  cm
  - $< 10$  mm depth of invasion
  - PLNDs (-)



- ***Parametrial involvement: 3 pts (0.6%)***

Covens et al., *Gynecol Oncol* 2002;84:145-149





# Parametrial Involvement in Radical Hysterectomy Specimens for Women With Early-Stage Cervical Cancer

*Michael Frumovitz, MD, MPH, Charlotte C. Sun, DrPH, Kathleen M. Schmeler, MD, Michael T. Deavers, MD, Ricardo dos Reis, MD, Charles F. Levenback, MD, and Pedro T. Ramirez, MD*

- **350 pts**
- 27 pts (7.7%) with para

## ➤ **Sub-group 125 pts:**

- **Tumor size < 2 cm**
- **LVSI (-)**
- **PLNDs (-)**

## ➤ **Parametrial involvement: 0%**






Contents lists available at ScienceDirect

## Gynecologic Oncology

journal homepage: [www.elsevier.com/locate/ygyno](http://www.elsevier.com/locate/ygyno)



### Review

# Management of low-risk early-stage cervical cancer: Should conization, simple trachelectomy, or simple hysterectomy replace radical surgery as the new standard of care? ☆



Pedro T. Ramirez <sup>a,\*</sup>, Rene Pareja <sup>b</sup>, Gabriel J. Rendón <sup>b</sup>, Carlos Millan <sup>c</sup>,  
Michael Frumovitz <sup>a</sup>, Kathleen M. Schmeler <sup>a</sup>

<sup>a</sup> Department of Gynecologic Oncology and Reproductive Medicine, The University of Texas MD Anderson Cancer Center, Houston, TX 77030, USA

<sup>b</sup> Department of Gynecologic Oncology, Instituto de Cancerología Las Américas, Medellín, Colombia

<sup>c</sup> Department of Gynecology, Hospital Quiron, Murcia, Spain





Surgical procedure in published studies of conservative surgical treatment for early-stage cervical cancer.

Author (year)	No. of planned surgeries	Sentinel lymph node biopsy	Radical hysterectomy	Less radical procedures	Positive lymph nodes	Adjuvant radiotherapy	Adjuvant chemotherapy	Follow-up time, median (range), months	Relapses	Deaths
Rob [13]	40	Yes	6	Cone biopsy + PLND = 10 Simple trach + PLND = 24	6	0	0	47 (12-102)	1	0
Pluta [14]	60	Yes	3	TH + PLND = 57	5	5	0	47 (12-92)	0	0
Maneo [15]	37	No	N/A	Cone biopsy + PLND = 36	0	0	0	66 (18-168)	1	1
Fagotti [16]	17	No	4	Cone biopsy + PLND = 13	1	0	2	16 (8-101)	0	0
Palaia [17]	14	No	0	Simple trach + PLND = 14	0	0	0	38 (18-96)	0	0
Raju [18]	15	No	0	Simple trach + PLND = 15	0	0	0	96 (12-120)	0	0
Biliatis [19]	62	No	0	Cone biopsy + PLND = 35 <sup>a</sup> TH + PLND = 27 <sup>b</sup>	1	0	0	56 (13-132)	0	0
Plante [20]	16	Yes	0	Simple trach + PLND = 16 <sup>c</sup>	0	0	0	27 (1-65)	0	0
Total	261		13	247	13	5	2		2	1

PLND, pelvic lymphadenectomy; TH, total hysterectomy; trach, trachelectomy.

<sup>a</sup> No PLND in 4 patients.

<sup>b</sup> No PLND in 1 patient.

<sup>c</sup> Six patients had sentinel lymph node mapping alone.





# ANTICANCER RESEARCH

## Minimizing Fertility-sparing Treatment for Low Volume Early Stage Cervical Cancer; Is Less the (R)Evolution?

CHARALAMPOS THEOFANAKIS<sup>1</sup>, DIMITRIOS HAIDOPOULOS<sup>1</sup>, NIKOLAOS THOMAKOS<sup>1</sup>,  
ALEXANDROS RODOLAKIS<sup>1</sup> and CHRISTINA FOTOPOULOU<sup>2</sup>

*<sup>1</sup>Unit of Gynecologic Oncology, 1<sup>st</sup> Department of Obstetrics & Gynecology, Alexandra Hospital, National and Kapodistrian University of Athens, Athens, Greece;*

*<sup>2</sup>Imperial College Healthcare NHS Trust, Hammersmith Hospital, London, U.K.*

2020 Jul;40(7):3651-3658





Table I. Simple conization and lymphadenectomy for early-stage cervical cancer.

Study	N	FIGO stage	Histology	LNDs removed	LVSI	Recurrences	Obstetrical outcome
Andikyan, 2013 (13)	10	IA1: 7 (LVSI+) IB1: 3	SCC: 8 Adenoca: 1 Clear cell: 1	SLN	7	0	3 (no further information)
Bouchard-Fortier, 2014 (11)	17	IA2:4 IB1:13	SCC: 12 Adenoca: 4 Glassy cell: 1	18	4	0	Term: 2 Miscarriages: 0
Lindsay, 2014 (14)	43	IA1: 2 IA2: 4 IB1: 37	SCC: 28 Adenoca: 11 Adenosq: 4	18.5	16	2	Term: 10 Preterm:4 Miscarriage: 1 Termination: 1
Ditto, 2014 (15)	22	IA2: 6 IB1: 16	SCC: 10 Adenoca: 11 Adenosq: 1	26	9	2	Term: 4 Preterm: 1 Miscarriage: 1
Tomao, 2017 (12)	54	IA2:13 IB1: 41	SCC: 33 Adenoca: 19 Adenosq: 2	22.4	12	7	Term: 19 Miscarriages:1





Table II. *Simple vaginal trachelectomy for early-stage cervical cancer.*

Study	N	FIGO stage	Histology	Procedure	LVSI	Recurrences	LNDs removed	Obstetrical outcome
Slama, 2016 (17)	32	IA2: 7 IB1: 23 IB2: 2	SCC: 21 Adenoca: 3 Adenosq: 2	SVT: 11 Cone: 21	20	SVT: 2 Cone: 4	Not reported	Term: 4 Preterm: 1 Miscarriage: 1
Plante, 2017 (16)	35	IA1+LVSI: 8 IA2: 9 IB1: 18	SCC: 19 Adenoca: 13 Adenosq: 1 Clearcell: 1 Undif: 1	SVT: 35	9	1	15	Term: 18 Preterm: 2 Miscarriage: 5
Demirkiran, 2018 (18)	14	IA1+LVSI: 3 IA2: 4 IB1: 7	SCC: 12 Adenoca: 2	SVT: 13*	7	0	Not reported	Term: 4 Preterm: 2 Miscarriage: 1





Table III. *Parametrial involvement in early-stage cervical cancer.*





Study	N	FIGO stage	No of patients	LVSI		PI		Tumor size	No of patients
				No	Yes	No	Yes		
Baiocchi, 2017 (31)	345	IA2	13	228	103	329	16 <sup>a</sup>	≤2 cm	107
		IB1	273				>2 cm	190 <sup>b</sup>	
		IB2	59						
Pareja, 2018 (32)	30	IA2	9	12	6	30	0	<10 mm	22
		IB1	21				10-20 mm	8	

<sup>a</sup>Missing data for 14 patients; <sup>b</sup>Missing data for 48 patients.





# ConCerv: a prospective trial of conservative surgery for low-risk early-stage cervical cancer

Kathleen M Schmeler <sup>1</sup>, Rene Pareja <sup>2</sup>, Aldo Lopez Blanco,<sup>3</sup> Jose Humberto Fregnani,<sup>4</sup> Andre Lopes,<sup>5</sup> Myriam Perrotta,<sup>6</sup> Audrey T Tsunoda,<sup>7</sup> David F Cantú-de-León,<sup>8</sup> Lois M Ramondetta,<sup>1</sup> Tarinee Manchana,<sup>9</sup> David R Crotzer,<sup>10</sup> Orla M McNally,<sup>11</sup> Martin Riege,<sup>12</sup> Giovanni Scambia,<sup>13</sup> Juan Manuel Carvajal,<sup>14</sup> Julian Di Guilmi,<sup>15</sup> Gabriel J Rendon <sup>16</sup>, Preetha Ramalingam,<sup>17</sup> Bryan M Fellman,<sup>18</sup> Robert L Coleman,<sup>19</sup> Michael Frumovitz <sup>1</sup>, Pedro T Ramirez<sup>1</sup>

- 100 pts
- St IA2 – IB1
- Tumor size < 2cm
- DOI < 10mm
- LVSI (-)
- Squamous Gr 1,2,3 or adenoca Gr 1,2
- Cone and ECC negative or CIN/AIS





Positive LNDs: 5%

Occult disease after cone resection: 2.5%

2year recurrence rate: 3.5%

2.4% (1/42) in patients after cone resection

0% (0/36) in patients that had a hystrectomy after cone resection

12.5% (2/16) in patients that had a simple hysterectomy

No parametrial recurrence

Schmeler et al., *Int J Gynecol Cancer* 2021;31:1317-1325



# SHAPE trial



The SHAPE study included 700 patients aged 24 to 80 years with low-risk, early-stage cervical cancer, defined as stage IA2 or IB1 disease; grade 1, 2, or 3; with lesions  $\leq 2$  cm. The participants, who came from 12 different countries, were randomly assigned to receive pelvic node dissection and either radical hysterectomy or simple hysterectomy. Half of the hysterectomies were done laparoscopically (56% of simple procedures vs 44% of radical procedures), 25% were done robotically (24% of simple vs 25% of radical), and 23% were done abdominally (17% simple vs 29% radical).

The primary endpoint of the study was to determine whether the pelvic recurrence rate at 3 years for simple hysterectomy was noninferior to radical hysterectomy. In order to demonstrate noninferiority of simple to radical hysterectomy, the upper limit of a one-sided 95% confidence interval for the difference in the pelvic recurrence rate at 3 years had to be lower than or equal to 4%. Secondary endpoints included extrapelvic relapse-free survival, relapse-free survival, overall survival, and quality of life.

## KEY POINTS

- The pelvic recurrence rate at 3 years with simple hysterectomy (2.5%) was not inferior to radical hysterectomy (2.2%).
- Extrapelvic relapse-free survival and overall survival were also comparable between the two groups.
- Patients in the simple hysterectomy group experienced fewer intraoperative urologic surgical complications and fewer immediate and long-term bladder problems. Several quality-of-life aspects—such as body image, pain, and level of sexual activity—were also more favorable in the simple hysterectomy group.



Marie Plante, Janice S. Kwon, Sarah Ferguson, Vanessa Samouëlian, Gwenaël Ferron, Amandine Maulard, Cor de Kroon, Willemien Van Driel, John Tidy, Christian Marth, Karl Tamussino, Stefan Kommos, Frederic Goffin, Brynhildur Eyjólfsdóttir, Jae-Weon Kim, Noreen Gleeson, Juliana M Ubi, Lori Brotto, Dongsheng Tu, Lois E. Shepherd





---

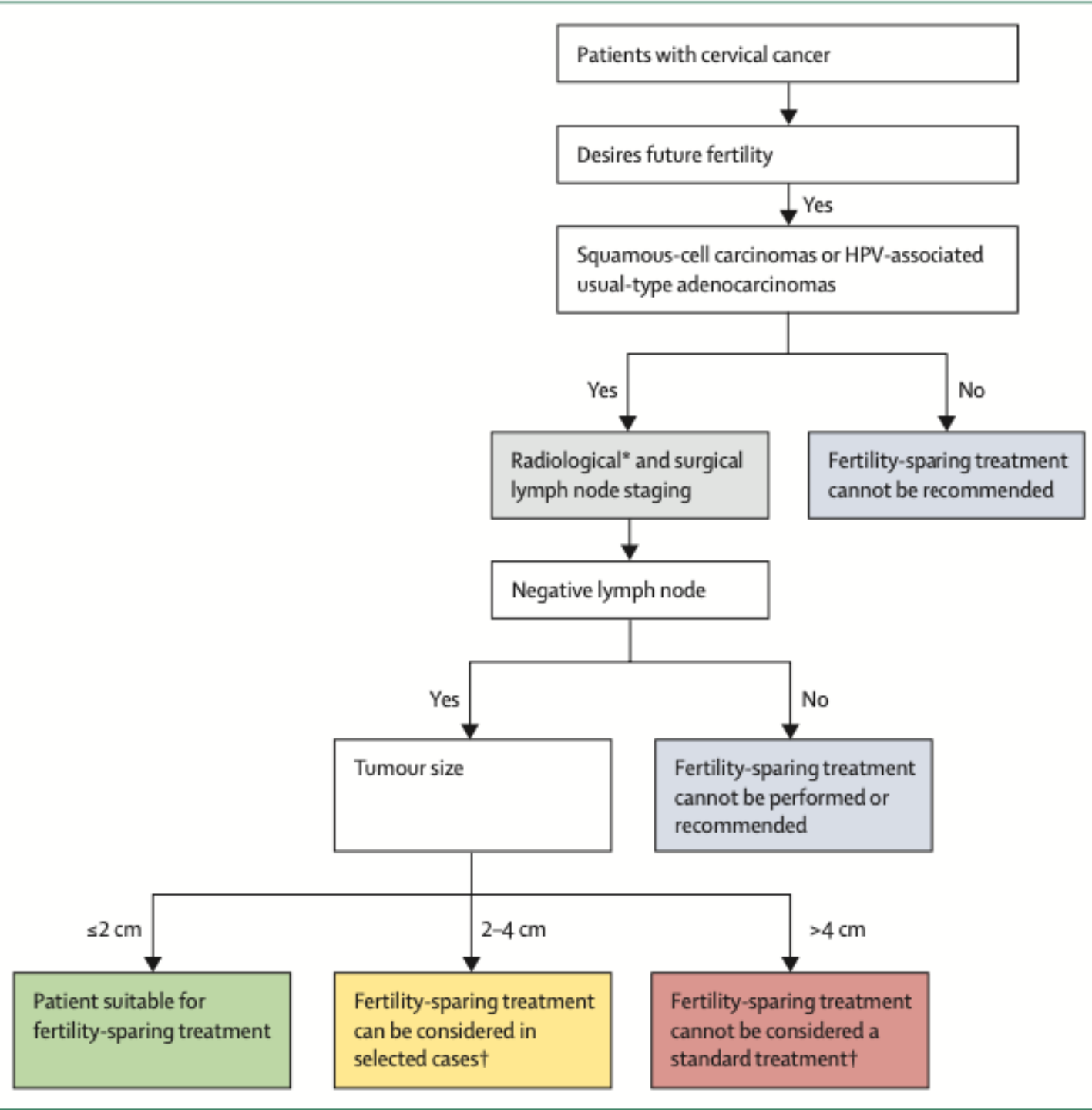
## Fertility-sparing treatment and follow-up in patients with cervical cancer, ovarian cancer, and borderline ovarian tumours: guidelines from ESGO, ESHRE, and ESGE



*Philippe Morice, Giovanni Scambia, Nadeem R Abu-Rustum, Maribel Acien, Alessandro Arena, Sara Brucker, Ying Cheong, Pierre Collinet, Francesco Fanfani, Francesca Filippi, Ane Gerda Zahl Eriksson, Sebastien Gouy, Philipp Harter, Xavier Matias-Guiu, George Pados, Maja Pakiz, Denis Querleu, Alexandros Rodolakis, Christine Rousset-Jablonski, Artem Stepanyan, Antonia Carla Testa, Kirsten Tryde Macklon, Dimitrios Tsolakidis, Michel De Vos, François Planchamp, Michaël Grynberg*

*Lancet Oncol 2024*







## Χειρουργικά και παθολογοανατομικά κριτήρια

- Radical trachelectomy with removal of a part of parametria is not recommended for stage IB1 disease fulfilling all the strict inclusion criteria of the ConCerv trial (III,E)
- Radical trachelectomy is recommended for stage IB2 disease by use of an abdominal approach (eg, laparotomy or mini-invasive approaches [robotic-assisted or pure laparoscopic approaches])  
(IV, B)
- Lymph node staging strategies for stage IB1 and IB2 diseases should follow the ESGO–ESTRO–ESP guidelines (IV, B)
- Negative margins (a non-fragmented specimen, with at least 1 mm histological-free margin from carcinoma or dysplasia) are mandatory. A non-fragmented cone is crucial for pathological evaluation. The base of the cone should encompass the visible gross lesion on the ectocervix with at least 1 mm histological margin (III, A)
- The height of the cone (centre of cone base to vertex) should be at least 10 mm. Cones can be oriented with a suture at the midpoint of the anterior cervical lip (IV, B)





## Χειρουργικά και παθολογοανατομικά κριτήρια

- Negative pelvic nodal status is mandatory for any fertility-sparing therapy. For assessing the pelvic nodal staging, ESGO–ESTRO–ESP guidelines should be followed (IV, A)
- Pelvic nodal staging is not indicated in T1a1 LVSI-negative tumours that have negative margins on conisation (IV, D)
- Intraoperative frozen section of cone margins can be considered to tailor the surgery (IV, B)





## Κριτήρια υπέρ της συντηρητικής αντιμετώπισης

1. Assignment of patients to favourable selection criteria is based on all clinicopathological variables (IV, B)
2. Confirmed histology on cervical biopsy or conisation is consistent with squamous cell carcinoma (all grades) or usual-type HPV-associated adenocarcinoma (all grades) with no more than 10 mm stromal invasion (IV, B)
3. Absence of LVSI is a favourable pathological biomarker (III, B)
4. No evidence of any metastasis is required (IV, A)
5. Largest measurement of a tumour is 2 cm by imaging or clinical exam (IV, B)
6. Free margins on final pathology are mandatory (III, A)
7. No evidence of tumour involvement of the internal cervical orifice and cranial extent of cervical tumour is 1 cm or more from the internal cervical orifice on imaging (IV, B).





## Κριτήρια κατά της συντηρητικής αντιμετώπισης (τουλάχιστον 1)

1. Any histological type other than squamous cell carcinoma and usual-type HPV-associated adenocarcinoma (mucinous-type HPV-associated carcinomas, gastric-type cervical adenocarcinoma, mesonephric carcinoma, small-cell neuroendocrine carcinoma, and clear cell carcinoma; IV, C)
2. Confirmed pelvic nodal involvement, extracervical tumour extension, evidence of tumour beyond the cervical ring, or metastasis (IV, B)
3. The largest tumour measurement is more than 4 cm by imaging or clinical exam (IV, B)
4. FIGO stage is IB3 or more (IV, B)
5. Tumour cranial extent is less than 5 mm from, or involves, the internal cervical orifice or lower uterine segment by imaging (IV, B)
6. Intraoperative frozen-section assessment of the resected cervical specimen for assessing the upper resection margin reveals a positive margin from the internal cervical orifice with inability to achieve a wider margin (IV, B)
7. Histologically confirmed endocervical margin, endocervical curettage above resection, or endometrial involvement on final pathology (IV, B)





## Ογκολογικά κριτήρια αποδεκτά σε επιλεγμένες περιπτώσεις

1. Tumour size is 2–4 cm by exam or imaging (IV, C)
2. Stromal invasion by conisation is more than 10 mm but has negative margins (IV, C)
3. Evidence of deep cervical stromal invasion on MRI or sonography (IV, B)
4. Tumour cranial extent is 5–10 mm from internal cervical orifice by imaging (IV, C)
5. Trachelectomy specimen margin reveals a 5–10 mm tumour-free margin from the internal cervical orifice (IV, B)
6. Silva pattern C of HPV-associated usual-type adenocarcinoma (data are scarce on pattern B with LVSI; IV, C).





## Νεοεπικουρική ΧΜΘ σε ασθενείς St IB2

- Neoadjuvant chemotherapy has been used by various investigators as an alternative to radical trachelectomy for selected patients with stage IB2 (2–4 cm) cervical cancer (IV, C)
- Various chemotherapy regimens have been used to reduce cervical tumour burden and allow for a satisfactory resection of the primary tumour with conisation and simple or radical trachelectomy (IV, C)
- Retrospective data suggest that abdominal radical trachelectomy has the lowest recurrence rate for patients with stage IB2 cervical cancer (IV, C)
- Ongoing prospective trials with platinum and paclitaxel will clarify the validity of neoadjuvant chemotherapy in fertility-sparing treatment of stage IB2 disease (IV, C)
- Including patients with stage IB2 cervical cancer in ongoing trials is encouraged to evaluate the safety of neoadjuvant chemotherapy (V, B)
- Confirming pathological-negative bilateral pelvic nodes (sentinel lymph node or lymphadenectomy) before starting neoadjuvant chemotherapy allows for the most accurate staging and selection of appropriate candidates for neoadjuvant chemotherapy approach (IV, B)
- Preoperative imaging with pelvic MRI and whole-body PET-CT is favoured (IV, B).





REVIEW

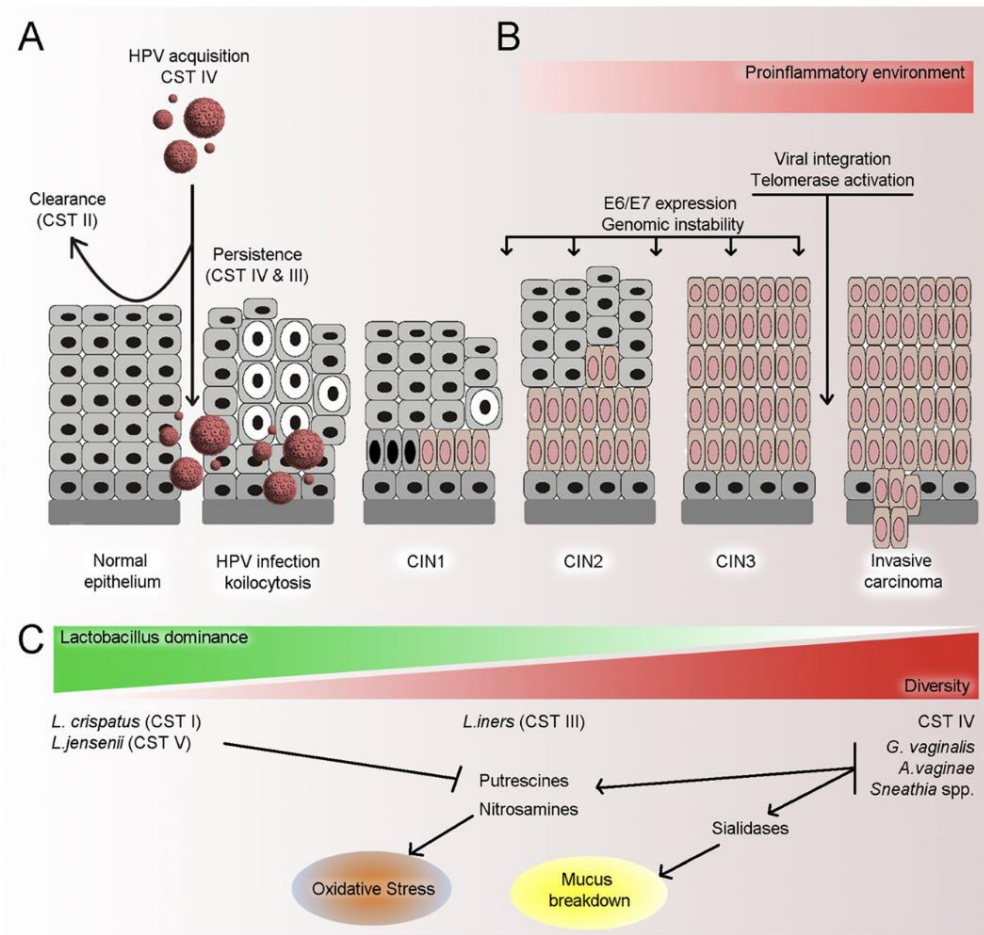
Open Access



# The vaginal microbiota, human papillomavirus infection and cervical intraepithelial neoplasia: what do we know and where are we going next?

Anita Mitra<sup>1,2</sup>, David A. MacIntyre<sup>1\*</sup>, Julian R. Marchesi<sup>3,4,5</sup>, Yun S. Lee<sup>1</sup>, Phillip R. Bennett<sup>1,2</sup> and Maria Kyrgiou<sup>1,2\*</sup>



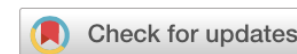

**Fig. 1** Summary of potential mechanisms associating the VMB with cervical disease. **a** VMB structure appears to be associated with acquisition and persistence of HPV infection, and CST II in particular is associated with most rapid clearance of an acute HPV infection. **b** Dysbiosis can result in a proinflammatory environment, which can facilitate several of the necessary steps in viral transformation including E6 and E7 expression, genomic instability, viral integration and telomerase activation, which are necessary for carcinogenesis. **c** Higher diversity with lower *Lactobacillus* spp. content has been associated with increasing severity of CIN. Particular species associated with high diversity VMBs may produce sialidases which cause mucus breakdown, predisposing the cervical epithelium to tissue damage, as well as producing biological amines which are responsible for oxidative stress; a key mechanism in carcinogenesis. Certain species *Lactobacillus* spp. have been shown to mop up these amines, and therefore their presence may reduce the risk of oxidative damage. *L. iners* does not appear to share many of the protective mechanisms of other *Lactobacillus* species and therefore appears intermediate in its ability to prevent cervical disease








ARTICLE



<https://doi.org/10.1038/s41467-020-15856-y>

OPEN

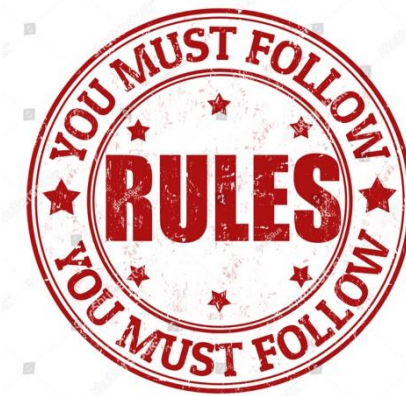# The vaginal microbiota associates with the regression of untreated cervical intraepithelial neoplasia 2 lesions

Anita Mitra <sup>1,2</sup>, David A. MacIntyre <sup>1,3</sup>, George Ntritsos<sup>4</sup>, Ann Smith<sup>5</sup>, Konstantinos K. Tsilidis<sup>4,6</sup>, Julian R. Marchesi<sup>3,7,8</sup>, Phillip R. Bennett<sup>1,2,3</sup>, Anna-Barbara Moscicki<sup>9,10</sup> & Maria Kyrgiou <sup>1,2,10</sup> ✉



# Συμπεράσματα

- Abdominal radical trachelectomy is the gold-standard for young patients with early-stage cervical cancer, who wish to preserve their fertility
- Tumors  $\leq 2$  cm, with  $< 10$  mm depth of invasion and without LVSI can be treated with less radical surgery
- **Less complications, better quality of life, with oncologic safety**
- Careful patient selection for radical hysterectomy to avoid adjuvant chemoradiation treatment
- Treatment in high-volume centers
- Decision within MDT



shutterstock

www.shutterstock.com



***„The talk and the relationship with the patient is the most relevant drug in medicine!“***



[ch.theofanakis@gmail.com](mailto:ch.theofanakis@gmail.com)  
6973042478